



# PURWANCHAL NAGARIK SAMITY

P-136, C.I.T. Road, Scheme - VIM, Kolkata - 700 054

Ph: +91 33 2320 2867, M: +91 90380 77719

E-mail : samity.pns@gmail.com, Website : www.purwanchal.org

পূর্বাঞ্চল নাগরিক সমিতি



Clinically faithful

Associate Code : D1  
Patient's Name : MS MADHURI MONDAL  
ID Number : PNS/79348/K-476/50  
Referred By : DR. VINOD KALA

Sample Cl.Date : 03/11/2015 0:00  
Test Comp.Date : 03/11/2015  
Age/Sex : 25Y/FEMALE  
Sample Source : DIRECT

ClinicPro/Kaber

Page 1 of 1

## U.S.G OF LOWER ABDOMEN

**URINARY BLADDER** : Urinary bladder is seen normal in size, shape and wall thickness.  
No intraluminal lesion is seen.

**UTERUS** : Uterus is normal in size, outline and has homogenous echopattern.  
No focal SOL is seen. Endometrial thickness is normal 7 mm .  
Cervix is normal. Uterus measures = 77 mm x 37 mm x 37 mm .

**OVARIES** : A thicked wall hemorrhagic cyst (51 x 38 mm) seen at right ovary .  
Left ovary is normal in size and echotexture. No focal lesion is seen.  
Left Ovary = 32 mm x 21 mm.

**POUCH OF DOUGLAS** : No fluid is seen.


**IMPRESSION** \*\* Right ovarian hemorrhagic cyst .

Follow up with TVS suggested .

\*\*\* Please correlate clinically \*\*\*

# End of Report #

  
DR. T. K. ROY  
MBBS, DMRD.



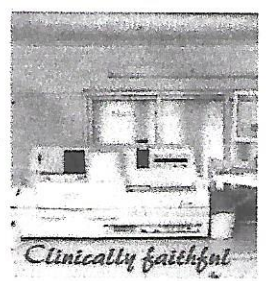
# PURWANCHAL NAGARIK SAMITY

P-136, C.I.T. Road, Scheme - VIM, Kolkata - 700 054

Ph : +91 33 2320 2867, M : +91 90380 77719

E-mail : samity.pns@gmail.com, Website : www.purwanchal.org

## पूर्वांचल नागरिक समिति



Associate Code : D1  
Patient's Name : MS MADHURI MONDAL  
ID Number : PNS/145871/H-3583/31  
Referred By : DR. V. KALA

Sample Cl.Date : 16/08/2016  
Test Comp.Date : 16/08/2016  
Age/Sex : 24Y/FEMALE  
Sample Source : DIRECT

ClinicPro/Kaberi

Page 1 of 1

### U.S.G OF LOWER ABDOMEN

**URINARY BLADDER** : Urinary bladder is seen normal in size, shape and wall thickness.  
No intraluminal lesion is seen.

**UTERUS** : Uterus is normal in size, outline and has homogenous echopattern.  
No focal SOL is seen. Endometrial thickness is normal 8 mm .  
Cervix is normal. Uterus measures = 78 mm x 35 mm x 45 mm

**OVARIES** : Left ovary is normal in size and echotexture. No focal lesion is seen.  
One clear cyst (27 x 28 mm) seen at right ovary .

**POUCH OF DOUGLAS** : No fluid is seen.

**IMPRESSION** ( \*\* Right ovarian cyst .

\*\*\* Please correlate clinically \*\*\*

# End of Report #

FOR & T-300  
ASSISTANT, KALKA

DR. TARUN KUMAR POY  
MBBS, D.F.M. (CO.)  
CONSULTANT RADIOLOGIST & GONCOLOGIST  
REG NO. 52033 (WB)